



# South Asian Journal of Cancer

Volume 8 • Issue 1 • January-March 2019

○ Treatment of advanced NSCLC - Indian consensus statement update

○ PIPAC for peritoneal carcinomatosis

○ Nimotuzumab with CRT in HNSCC

○ Primary Gastrointestinal DLBCL

Brought to you by:

**(M<sup>i</sup>)**  
**MEDINTEL**  
Enhancing The Value of Science

**Editor in Chief: Dr. Sachin Hingmire**

**Joint Editors: Dr. Kumar Prabhash  
Dr. Prasad Narayanan**

Supported by:



**PubMed**  
Indexed

Medknow

 Wolters Kluwer

# Safety and efficacy of nimotuzumab with concurrent chemoradiotherapy in unresectable locally advanced squamous cell carcinoma of head and neck: An Indian rural hospital experience

Shyamji Rawat, Hemu Tandan, Sanandan Patel, Sameer Chaudhari

## Abstract

**Context:** Nimotuzumab is the only anti-epidermal growth factor receptor monoclonal antibody which can be safely added to concurrent chemoradiotherapy (CRT) to improve efficacy in the management of unresectable, locally advanced squamous cell carcinoma of head and neck (LA-SCCHN). However, the evidence available on this is limited. **Aims:** We retrospectively investigated efficacy and safety of nimotuzumab when combined with chemoradiation for LA-SCCHN. **Settings and Design:** Hospital records of 39 patients from January 2012 to December 2016 diagnosed with locally advanced (Stage III-IVb), unresectable SCCHN, and treated with concurrent CRT with weekly nimotuzumab were reviewed retrospectively after fulfilling the inclusion/exclusion criteria. **Subjects and Methods:** Tumor response was calculated as per response evaluation criteria in solid tumors criteria 1.1. Association of tumor response with independent variables was assessed. Overall survival (OS) and progression-free survival (PFS) were calculated. All patients were assessed for toxicity as per common terminology criteria for adverse events Common Terminology Criteria for Adverse Events v 4.0 (U.S. Department of health and human services, National Institutes of Health, National Cancer Institute). **Results:** At 6 months after completion of treatment, objective response rate was 97.44% with 26 (66.67%) patients attaining Complete response (CR), 12 (30.77%) patients with Partial response (PR), and one patient (2.56%) had stable disease. Subgroup analysis did not show a significant association of tumor response with independent factors. OS at 1 and 2-year was 100% and 72.9%, while PFS at 1 and 2-year was 87% and 54.40%. The incidence of Grade I, II, III, and IV toxicity was 30%, 18.18%, 41.82%, and 10%, respectively. No grade V toxicity was observed. Common adverse events observed were mucositis (33.64%), skin reaction (24.55%), neutropenia (20.91%), vomiting (18.18%), and diarrhea (2.73%). **Conclusions:** Nimotuzumab is an efficacious and safe option when added to concurrent CRT in unresectable, LA-SCCHN.

**Key words:** Advanced, antibodies, carcinoma, head and neck neoplasms, inoperable, Monoclonal, Nimotuzumab, Overall survival, squamous cell, therapy

## Introduction

Squamous cell carcinoma of the head and neck (SCCHN) accounts for a significant portion of the oncology burden in India.<sup>[1,2]</sup> Cigarette-smoking and alcohol consumption are the main factors for SCCHN in the Western population,<sup>[3]</sup> whereas the use of tobacco chewing, Areca nut and Epstein-Barr virus being a common cause of SCCHN in Southeast Asian population.<sup>[1,2]</sup> The majority of the patients with SCCHN in India presents an advanced stage and pose a challenge for treatment.<sup>[4,5]</sup> Advanced Stage (III or IV) often requires multimodal therapy, consisting of a combination of surgery, radiotherapy (RT), and/or chemotherapy.<sup>[6]</sup> Concurrent chemoradiotherapy (CRT) is the standard of care in patients with locally advanced SCCHN (LA-SCCHN) who are considered for nonsurgical approach. Concurrent cisplatin-based CRT has demonstrated the best outcome, and survival benefits in unresectable, LA-SCCHN in combined treatment strategies, but are associated with increased risk of toxicity and the 5-year survival being limited to <50%.<sup>[7]</sup>

Thus, the quest for balancing the clinical outcomes and toxicity without compromising the survival benefits led to molecular biological targets for alternative therapy approaches. Expression of the epidermal growth factor receptor (EGFR) is detected in more than 90% of all cases of SCCHN and has been correlated with decreased survival rates, resistance to RT, chemotherapy treatment failure, and increased rates of distant metastases.<sup>[8]</sup>

Thus, molecular-targeted therapies focusing on EGFR have attracted attention as a potential molecule for the treatment of head and neck cancers.

EGFR-targeted monoclonal antibodies (anti-EGFR Mab), cetuximab, and nimotuzumab are approved to be used in

combination with chemotherapy/RT, and these molecules have shown promising results with improvement in progression-free survival (PFS) and overall survival (OS) in SCCHN.<sup>[9]</sup> Based on the evidence that anti-EGFR MABs also sensitized the tumors to radiation<sup>[10-12]</sup> or cisplatin,<sup>[13,14]</sup> they have been explored as add-on therapy with concurrent CRT in SCCHN.

Cetuximab is a chimeric human/murine anti-EGFR MAB. Pfister *et al.*, in phase two trials reported likely clinical outcome and survival benefit with cetuximab plus CRT in LA-SCCHN. However, due to drug-related toxicities, serious adverse events and deaths led to early closure of the study.<sup>[15]</sup> However, RTOG 0522 (phase three) trial, at a median follow-up time of 3.8 years failed to demonstrate a survival benefit with the combination of cetuximab and chemoradiation over the standard chemoradiation and was also associated with more treatment-related grade five adverse events, frequent interruptions in radiation therapy and 10% increase in grade three and four dermatitis and mucositis.<sup>[16]</sup>

On the other hand, nimotuzumab (BIOMAb EGFR<sup>®</sup>) is a humanized anti-EGFR MAB that binds to the extracellular domain of the EGFR with intermediate affinity and high specificity. Reddy *et al.*, in Phase IIb (BEST) trial among the Indian population with inoperable, LA-SCCHN also reported higher and statistically significant tumor response rate, 5-year PFS and 5-year OS in nimotuzumab + CRT arm than in the CRT arm. The risk of death was 64% lower with CRT + nimotuzumab than with CRT. The addition of nimotuzumab was well tolerated with few mild-to-moderate self-limiting adverse events. The trial demonstrated that concurrent use of nimotuzumab with CRT was safe and provided with a long-term survival benefit in inoperable, LA-SCCHN.<sup>[17]</sup>

This is an open access journal, and articles are distributed under the terms of the Creative Commons Attribution-NonCommercial-ShareAlike 4.0 License, which allows others to remix, tweak, and build upon the work non-commercially, as long as appropriate credit is given and the new creations are licensed under the identical terms.

**For reprints contact:** reprints@medknow.com

**How to cite this article:** Rawat S, Tandan H, Patel S, Chaudhari S. Safety and efficacy of nimotuzumab with concurrent chemoradiotherapy in unresectable locally advanced squamous cell carcinoma of head and neck: An Indian rural hospital experience. South Asian J Cancer 2019;8:52-6.

Access this article online

Quick Response Code:



Website: www.sajc.org

DOI: 10.4103/sajc.sajc\_76\_18

Department of Radiation Oncology, NSCB Medical College and Government Hospital, Jabalpur, Madhya Pradesh, India

**Correspondence to:** Dr. Shyamji Rawat, E-mail: drshyamjirawat@yahoo.co.in

However, clinical studies to substantiate these findings are few and limited in India.<sup>[18-20]</sup> Therefore, we retrospectively investigated the efficacy and safety of nimotuzumab in combination with concurrent chemoradiation for unresectable, LA-SCCHN.

## Subjects and Methods

We retrospectively evaluated the safety and efficacy of nimotuzumab with concurrent CRT in unresectable, locally advanced head and neck carcinoma (HNC) after obtaining approval from the institutional review board. The hospital records of LA-SCCHN patients were reviewed who received nimotuzumab with concurrent CRT from 2012 to December 2016 at a Government Hospital in Jabalpur (India).

We selected cases based on the following inclusion criteria (a) histologically confirmed SCCHN; (b) with disease classified as Stage III–IVb; (c) patients of age 18 years and above; (d) Eastern cooperative oncology group (ECOG) performance score  $\leq 2$ ; (e) cisplatin-based concurrent chemotherapy; (f) radiation therapy with total dose  $>50$  Gy, up to 70 Gy; and (h) Treated with nimotuzumab 200 mg weekly. We excluded the following cases (a) Non-HNC; (b) recurrent/metastatic HNC; (c) salivary gland cancer; (d) paranasal sinus cancer; (e) nasopharyngeal cancer; (f) undergone prior surgery; and (h) prior treated with other anti-EGFR based therapy.

The information was collected from the hospital records of individual patients. Clinical data of patients were collected, including diagnosis, age, gender, pathological type, tumor stage, tumor grade, and ECOG score, investigations, clinical course, with details of concurrent chemotherapy, RT, and nimotuzumab therapy.

## Evaluating parameters

The antitumor response was evaluated after 24 weeks of treatment, according to response evaluation criteria in solid tumors (RECIST 1.1) and included criteria complete remission (CR), partial remission (PR), stable disease (SD), and progression disease. The objective response rate (ORR) =  $(CR + PR) \times 100\%$  was calculated. OS was defined as the time from the date of diagnosis to the date of death because of any causes or the last follow-up/last contact (visit and telephone). PFS was defined as the time from the date of diagnosis until the date of the tumor progression or death. An association of tumor response with various independent factors (age, gender, histopathological grades, and tumor-node-metastasis [TNM] stages) was further analyzed. All patients were assessed for toxicity, and adverse events were reported as per common terminology criteria for adverse events v 4.0

## Statistical analysis

Statistical analysis was performed using SPSS software (version 19.0, IBM corp., Armonk, New York, US). Data were expressed in descriptive statistics. Median OS and PFS along with 95% confidence interval (CI) was estimated by the Kaplan–Meier curve. An association between the variables was estimated by Chi-square test and Fisher's exact probability test, as appropriate.  $P < 0.05$  was considered statistically significant.

## Results

A total of 42 patients with locally advanced (Stage III–IVb) HNC treated with nimotuzumab with concurrent chemoradiation were identified. Of these, three patients who had undergone prior surgery were excluded, and the final analysis was done in 39 patients.

## General characteristics

The mean age of the patients was  $57.7 \pm$  years, with majority 30 (76.9%) being males and 9 (23.1%) females. Patients with age below 65 years were 31 (79.5%) and age  $\geq 65$  years were 8 (20.5%). Majority of the patients had Stage III disease (79.4), and the most commonly treated site of cancer was oral cavity (61.5%), followed by oropharynx (30.8%) and larynx (7.7%) [Table 1]

## Efficacy

Antitumor response: At 24 weeks (6 months) after the treatment, 26 (66.7%) patients had attained complete response (CR) and 12 (30.7%) patients had achieved partial response (PR), whereas 1 (2.6%) patient showed SD, respectively. The objective response rate (CR + PR) achieved was 97.4% [Table 1].

## Survival outcome

The 1 and 2-year OS rates achieved with nimotuzumab and concurrent chemoradiation were 100% and 72.9% [Figure 1], while the 1 and 2-year PFS rates were 87% and 54.40%, respectively [Figure 2]. The median OS and PFS were not reached (NR).

## Association of tumor response with independent factors

Subgroup analysis did not show a significant association of tumor response with various subgroups, though patients with age  $\geq 65$  years, male gender, laryngeal cancer, tumor Grade III, and TNM Stage III had a higher frequency of CR [Table 1].

## Safety and toxicity

The most common adverse events encountered during treatment were mucositis (33.64%), followed by skin reaction (24.55%), neutropenia (20.91%), vomiting (18.18%), and diarrhea (2.73%). The detailed toxicity and their grades of the combination therapy are summarized in Table 2. Nimotuzumab was observed to be safe with no additional adverse events (hypersensitivity, allergic reactions, and skin changes) reported during the study.

## Discussion

The findings of the present retrospective study indicate that the addition of nimotuzumab to concurrent CRT contributes to improve the therapeutic and survival outcome in patients with unresectable LA-SCCHN.

Treatment of patients with locally, unresectable advanced HNCs remains a challenge despite concurrent CRT as the standard of care therapy.

EGFR represents a promising new molecular target in head and neck cancer. The overexpression of the EGFR is closely related to tumor cell growth, proliferation, invasion, metastasis, apoptosis, and poor prognosis of the disease. Inhibiting EGFR pathway can inhibit tumor cell proliferation, differentiation, tumor angiogenesis, and promote treatment response of chemotherapy and radiation.<sup>[21]</sup>

Several clinical trials have evaluated the role of Anti-EGFR Mabs in combination with concurrent CRT to improve the therapeutic and survival outcomes in LA-SCCHN.<sup>[15-17,22]</sup> Cetuximab in the early phase trial by Pfister *et al.* documented beneficial therapeutic and survival outcomes with a combination of chemoradiation over the standard chemoradiation in the advanced setting, but was limited by serious treatment toxicities, therefore, closed prematurely.<sup>[15]</sup> Based on the beneficial therapeutic and survival achieved in early phase trial, a Phase III RTOG 0522 trial was initiated. However, the combination of



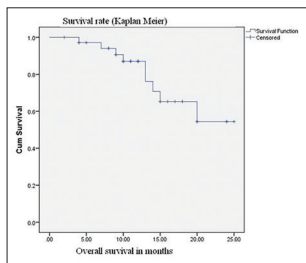
**Table 1: Characteristics and analysis of factors associated with tumour response rate**

Parameters	Number of patients (%)	CR (%)	PR (%)	SD (%)	P
Gender					
Female	9 (23.07)	4 (44.44)	5 (55.56)	0	0.174
Male	30 (76.92)	22 (73.33)	7 (23.33)	1 (3.33)	
Age (years)					
<65	31 (79.49)	20 (64.52)	10 (32.26)	1 (3.23)	1
≥65	8 (20.51)	6 (75)	2 (25)	0	
Anatomical subsites					
Larynx	3 (7.69)	3 (100)	0	0	0.0544
Oral cavity	24 (61.54)	12 (12)	11 (45.83)	1 (4.17)	
Oropharynx	12 (30.77)	11 (91.67)	1 (8.33)	0	
Histopathology grade					
1	4 (10.26)	2 (50)	2 (50)	0	0.6509
2	16 (41.03)	10 (62.5)	6 (37.5)	0	
3	17 (43.59)	12 (70.59)	4 (23.53)	1 (5.88)	
TNM stage					
Stage III	31	19	11	1 (3.23)	0.5178
Stage IV	8	7	1	0	
Total	39 (100)	26 (66.67)	12 (30.77)		

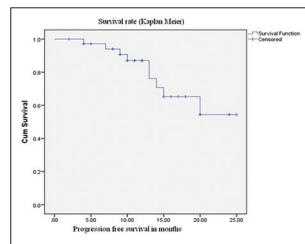
CR=Complete remission, PR=Partial remission, SD=Stable disease, TNM=Tumor node metastasis

**Table 2: Common adverse events encountered during the treatment**

Adverse events	Grade 1 (%)	Grade 2 (%)	Grade 3 (%)	Grade 4 (%)	Total (%)
Neutropenia	17 (15.45)	6 (5.45)	0	0	23 (20.91)
Mucositis	0	7 (6.36)	23 (20.91)	7 (6.36)	37 (33.64)
Vomiting	15 (13.64)	3 (2.73)	2 (1.82)	0	20 (18.18)
Diarrhea	1 (0.91)	1 (0.91)	1 (0.91)	0	3 (2.73)
Skin reaction	0	3 (2.73)	20 (18.18)	4 (3.64)	27 (24.55)
Total	33 (30)	20 (18.18)	46 (41.82)	11 (10)	110 (100)



**Figure 1: Overall survival of locally advanced squamous cell carcinoma of head and neck patients who received nimotuzumab with concurrent chemoradiotherapy**



**Figure 2: Progression-free survival of locally advanced squamous cell carcinoma of head and neck patients who received nimotuzumab with concurrent chemoradiotherapy**

cetuximab with chemoradiation failed to demonstrate a survival benefit over the standard chemoradiation and was associated with more toxicity.<sup>[16]</sup> Similarly, other anti-EGFR Mab (panitumumab) did not show any significant beneficial outcome when combined with chemoradiation<sup>[22]</sup> with the exception of nimotuzumab based on the BEST trial,<sup>[17]</sup> though with limited data.

Nimotuzumab (BIOMab EGFR®) is a humanized anti-EGFR Mab that binds to the extracellular domain of the EGFR with intermediate affinity and high specificity. This results in the blockade of receptor-dependent signal transduction pathways and provides an antitumor response.<sup>[23]</sup> Nimotuzumab also enhances the tumor radio-sensitivity by inhibiting the radiation-induced activation of DNA-PKcs by blocking the PI3K/AKT pathway.<sup>[10]</sup> Thus, exerting dual mode of action.

The advantage of nimotuzumab over other anti-EGFR antibodies are its benign adverse effect profile (does not cause

severe skin toxicity or hypomagnesemia or gastrointestinal adverse events). The benign safety profile can be attributed to the fact that unlike other anti-EGFR antibodies, nimotuzumab requires bivalent binding for stable attachment, leading to selective binding to cells expressing moderate to high EGFR levels. When EGFR density is low, such as in normal tissues, monovalent interaction of nimotuzumab is transient, thus sparing healthy tissues and avoiding severe toxicities.<sup>[24]</sup> This explains nimotuzumab minimal treatment-related toxicities in clinical studies while demonstrating similar or superior antitumor effects as compared to other anti-EGFR Mabs.

In the present study, we found that the combination of Nimotuzumab with concurrent CRT resulted in clinical meritorious outcomes; the CR, PR, SD, and ORR at 24 weeks (6 months) after treatment were 66.7%, 30.7%, 2.6%, and 97.4%, respectively. The survival benefit achieved with the combination at 1 and 2-year were 100% and 72.9% while the 1 and 2-year PFS rates were 87% and 54.40%, respectively. The median OS and PFS were NR in this study. These findings are similar and in agreement with the BEST trial and several individual clinical studies.<sup>[17-20]</sup>

The BEST trial was a multicenter, randomized, open-label, Phase IIb, 5-year study, the first of its kind cohort conducted among the Indian population.<sup>[17]</sup> The study evaluated the safety and efficacy of nimotuzumab, administered along with CRT or RT in patients with inoperable, LA-SCCHN by assessing the short-term response (6 months) and 5-year survival. The study documented that ORR was significantly higher in the CRT + nimotuzumab arm than in the CRT arm (100% vs. 70%, *P* = 0.020) at 6-month posttreatment. The 5-year PFS was significantly higher in the

CRT + nimotuzumab arm than in the CRT arm (48% vs. 26%,  $P = 0.03$ ). The median 5-year PFS was 54.24 months in the CRT + nimotuzumab arm and was significantly higher than the 14.95 months observed in the CRT arm ( $P = 0.036$ ). Furthermore, the 5-year OS was significantly higher in the CRT + nimotuzumab arm than in the CRT arm (57% vs. 26%,  $P = 0.03$ ). The median 5-year OS was NR in the CRT + nimotuzumab arm at 60 months, whereas it was 21.94 months in the CRT arm ( $P = 0.0078$ ); the addition of nimotuzumab to CRT caused a 64% reduction in death risk (hazard ratio = 0.36, 95% CI: 0.37, 1.56). Nimotuzumab was found to be safe and well tolerated with few mild to moderate self-limiting adverse events. There were no significant differences in the hematological, biochemical, and urine analysis findings of patients in all study arms. No long-term drug-related toxicity was seen during the median follow-up of 65.7 months.<sup>[17]</sup> These findings strongly favored nimotuzumab as add-on therapy to standard of care of CRT.

A preliminary results of a clinical study by Bhatnagar and Singh of 56 patients with LA HNSCC who were randomized to CRT with or without nimotuzumab demonstrated significantly higher ORR with nimotuzumab + CRT with versus CRT alone (96% vs. 72%;  $P = 0.02$ ). Nimotuzumab did not potentiate toxicities of CRT, and there was no significant difference in the acute radiation mucositis, dermatitis, or hematological toxicities in both the groups ( $P > 0.05$ ), suggesting nimotuzumab can be safely added to standard CRT.<sup>[18]</sup> Similarly, Somani in an open-label, single arm clinical study of nimotuzumab with concurrent CRT in 57 patients with inoperable LASCCHN (stages III and IV) demonstrated better response rate with an ORR of 80.7% at 6-month posttreatment. However, the study did not capture the survival outcomes which limited the survival benefit offered by the combination. Mucositis (33%) was the most common encountered adverse event. No Grade III or IV adverse events were reported. Nimotuzumab did not exacerbate adverse events associated with concurrent CRT.<sup>[19]</sup> Similarly, Kumar and Mishra in a pilot study on 11 patients with Stage III and IV advance SCCHN demonstrated that combining nimotuzumab with concurrent chemoradiation, an ORR of 81% was achieved after 6 months' posttreatment in advanced SCCHN with acceptable toxicity.<sup>[20]</sup>

In the present study, the incidence of Grade I, II, III, and IV toxicity with the combination were 30%, 18.18%, 41.82%, and 10% respectively. No Grade V toxicity was observed. Common adverse events observed were mucositis, neutropenia, vomiting, diarrhea, and skin reaction which are similar to previous studies.<sup>[17-20]</sup> Nimotuzumab was observed to be safe with no additional adverse events (hypersensitivity, allergic reactions, and skin changes) reported during the study.

In summary, our results support and suggest that addition of nimotuzumab with concurrent CRT improves the tumor response rate and survival with minimal toxicities in patients with unresectable LA-SCCHN.

The study had a few limitations, first, retrospective design with a single arm assessment. Second, the retrospective data were collected from a single hospital setup and had a moderate sample size.

## Conclusions

Nimotuzumab can be safely added to the concurrent CRT treatment for locally advanced unresectable SCCHN, to achieve better

therapeutic response and improved survival outcomes without potentiating toxicity. Single-centered real-world evidence is consistent with the results shown in the previous randomized controlled trial.

## Acknowledgment

We would like to thank Ramez Ahmed for his valuable inputs and transcribing the manuscript.

## Financial support and sponsorship

Nil.

## Conflicts of interest

There are no conflicts of interest.

## References

- Dayal PK, Mani NJ, Bhargava K. Prevalence of oral cancer and precancerous lesions in 'pan'/'supari' chewers. *Indian J Public Health* 1978;22:234-45.
- Joshi P, Dutta S, Chaturvedi P, Nair S. Head and neck cancers in developing countries. *Rambam Maimonides Med J* 2014;5:e0009.
- Graham S, Dayal H, Rohrer T, Swanson M, Sultz H, Shedd D, et al. Dentition, diet, tobacco, and alcohol in the epidemiology of oral cancer. *J Natl Cancer Inst* 1977;59:1611-8.
- Parikh P, Patil V, Agarwal JP, Chaturvedi P, Vaidya A, Rathod S, et al. Guidelines for treatment of recurrent or metastatic head and neck cancer. *Indian J Cancer* 2014;51:89-94.
- Tuljapurkar V, Dhar H, Mishra A, Chakraborti S, Chaturvedi P, Pai PS, et al. The Indian scenario of head and neck oncology - Challenging the dogmas. *South Asian J Cancer* 2016;5:105-10.
- Puram SV, Rocco JW. Molecular aspects of head and neck cancer therapy. *Hematol Oncol Clin North Am* 2015;29:971-92.
- Pignon JP, le Maître A, Maillard E, Bourhis J; MACH-NC Collaborative Group. Meta-analysis of chemotherapy in head and neck cancer (MACH-NC): An update on 93 randomised trials and 17,346 patients. *Radiother Oncol* 2009;92:4-14.
- Agulnik M. New approaches to EGFR inhibition for locally advanced or metastatic squamous cell carcinoma of the head and neck (SCCHN). *Med Oncol* 2012;29:2481-91.
- Benson R, Mallick S, Julka PK, Rath GK. Anti EGFR therapy in the treatment of non-metastatic head and neck squamous cell carcinoma: The current evidence. *J Egypt Natl Canc Inst* 2016;28:141-8.
- Qu YY, Hu SL, Xu XY, Wang RZ, Yu HY, Xu JY, et al. Nimotuzumab enhances the radiosensitivity of cancer cells *in vitro* by inhibiting radiation-induced DNA damage repair. *PLoS One* 2013;8:e70727.
- Diaz-Miqueli A, Martinez GS. Nimotuzumab as a radiosensitizing agent in the treatment of high grade glioma: Challenges and opportunities. *Oncotargets Ther* 2013;6:931-42.
- Psyrris A, Yu Z, Weinberger PM, Sasaki C, Haffty B, Camp R, et al. Quantitative determination of nuclear and cytoplasmic epidermal growth factor receptor expression in oropharyngeal squamous cell cancer by using automated quantitative analysis. *Clin Cancer Res* 2005;11:5856-62.
- Fan Z, Baselga J, Masui H, Mendelsohn J. Antitumor effect of anti-epidermal growth factor receptor monoclonal antibodies plus cis-diamminedichloroplatinum on well established A431 cell xenografts. *Cancer Res* 1993;53:4637-42.
- Zhao L, Li QQ, Zhang R, Xi M, Liao YJ, Qian D, et al. The overexpression of IGFBP-3 is involved in the chemosensitivity of esophageal squamous cell carcinoma cells to nimotuzumab combined with cisplatin. *Tumour Biol* 2012;33:1115-23.
- Pfister DG, Su YB, Kraus DH, Wolden SL, Lis E, Aliff TB, et al. Concurrent cetuximab, cisplatin, and concomitant boost radiotherapy for locoregionally advanced, squamous cell head and neck cancer: A pilot phase II study of a new combined-modality paradigm. *J Clin Oncol* 2006;24:1072-8.
- Ang KK, Zhang Q, Rosenthal DI, Nguyen-Tan PF, Sherman EJ, Weber RS, et al. Randomized phase III trial of concurrent accelerated radiation plus cisplatin with or without cetuximab for stage III to IV head and neck carcinoma: RTOG 0522. *J Clin Oncol* 2014;32:2940-50.
- Reddy BK, Lokesh V, Vidyasagar MS, Shenoy K, Babu KG, Shenoy A, et al. Nimotuzumab provides survival benefit to patients with inoperable advanced squamous cell carcinoma of the head and neck: A randomized, open-label, phase IIb, 5-year study in Indian patients. *Oral Oncol* 2014;50:498-505.
- Bhatnagar AR, Singh DP. A comparative study of monoclonal antibody against EGFR (nimotuzumab) used in combination with chemoradiation versus chemoradiation alone in the treatment of locally advanced inoperable squamous cell carcinoma of the head and neck. *J Clin Oncol* 2012;Suppl 30:e16012.

19. Somani N. Nimotuzumab with concurrent chemo-radiotherapy in patients with locally advanced squamous cell carcinoma of head and neck. *J Cancer Ther* 2015;6:356-61.
20. Kumar A, Mishra KC. To assess the possibility of combining MAb (nimotuzumab) with concurrent chemoradiation in patients with locally advanced squamous cell carcinoma of head and neck. *Scientific Abstracts. Indian J Med Paediatr Oncol* 2012;33:1.
21. Wykosky J, Fenton T, Furnari F, Cavenee WK. Therapeutic targeting of epidermal growth factor receptor in human cancer: Successes and limitations. *Chin J Cancer* 2011;30:5-12.
22. Siu LL, Waldron JN, Chen BE, Winquist E, Wright JR, Nabid A, *et al.* Phase III randomized trial of standard fractionation radiotherapy (SFX) with concurrent cisplatin (CIS) versus accelerated fractionation radiotherapy (AFX) with panitumumab (PMab) in patients (pts) with locoregionally advanced squamous cell carcinoma of the head and neck (LA-SCCHN): NCIC Clinical Trials Group HN.6 trial. *J Clin Oncol* 2015;33(15\_suppl):6000.
23. Perez R, Moreno E, Garrido G, Crombet T. EGFR-targeting as a biological therapy: Understanding nimotuzumab's clinical effects. *Cancers (Basel)* 2011;3:2014-31.
24. Garrido G, Tikhomirov IA, Rabasa A, Yang E, Gracia E, Iznaga N, *et al.* Bivalent binding by intermediate affinity of nimotuzumab: A contribution to explain antibody clinical profile. *Cancer Biol Ther* 2011;11:373-82.